

EARLY ORTHODONTIC TREATMENT



*Brock Rondeau, D.D.S. I.B.O.,
D.A.B.C.P., D-A.C.S.D.D.,
D.A.B.D.S.M., D.A.B.C.D.S.M.*

I believe the time has come for the general dentists to get serious and educated in an effort to provide early orthodontic treatment for the children in their practice. Now there are two treatment philosophies regarding treatment of children in the mixed dentition. Many of us were taught in dental school not to treat in the mixed dentition but to refer the children at age 12 to an orthodontist when all the permanent teeth erupt. I know of no other medical or dental problems that occur in children that are delayed until all the permanent teeth erupt. In my opinion, it is completely illogical not to intervene at an early age when the research confirms that malocclusions left untreated worsen over time. Functional and skeletal problems are ideally treated in the mixed dentition when the children are more cooperative.

Dr. Charles Tweed, one of the world's most famous orthodontists (developed the Tweed Technique), produced excellent results throughout his career using fixed appliances. Near the end of his career, he stressed the importance of treating children in the mixed dentition. He stated, "In other words, knowledge will gradually replace harsh mechanics and, in the not too distant future, the vast majority of orthodontic treatment will be carried out in the mixed dentition period of growth and development prior to the difficult age of adolescence." Dr. Tweed made these remarks in 1963. Now, while more and more general dentists and orthodontists are treating in the mixed dentition many orthodontic practitioners have not been trained to offer this essential health service for our children.

Orthodontics means the straightening of teeth. Orthopedics means correcting the bone or skeletal problems. My treatment philosophy is to try to correct the skeletal (orthopedic) problem in the mixed dentition before

the eruption of the permanent teeth. There are numerous functional orthopedic appliances, fixed and removable, that can help accomplish this objective while the child is actively growing. Since 90% of the face is developed by age 12, if you want to positively modify the growth of the patient you must intervene at an early age. It has been estimated that approximately 75% of children have some form of malocclusion by age 12; therefore, it is critical that treatment be initiated early in order to avoid more lengthy and costly treatment later on.

The purpose of this article is to demonstrate some functional appliances that can be used in the mixed dentition to correct Class I, Class III and Class III malocclusions.

General dentists should be offering early orthodontic treatment to the children in their practices for the following reasons;

- There are a large number of children in your practice that need treatment.
- Most dental schools and orthodontic graduate programs in North America do not teach techniques to treat children in the deciduous and mixed dentition.
- When functional, skeletal and dental problems are treated in the deciduous and mixed dentition, this can usually prevent the extraction of permanent teeth and orthognathic surgery in the permanent dentition.
- Mothers are looking for dentists who can treat their children's malocclusions at an early age. They do not want to wait until the malocclusion gets worse and the cost for orthodontic treatment increases.
- Early orthodontic treatment for children will help increase your personal satisfaction from your practice when you start to see the positive influence you have on the children's personality and self-esteem.
- Why would you refer out 50 orthodontic cases per year at \$5,500 per case when you can retain the \$275,000 in your bank account?

- Functional problems such as airway constriction due to enlarged tonsils or adenoids which cause anterior open bites due to tongue thrusts must be dealt with early in the mixed dentition. Much easier to motivate a younger child to wear functional appliances with tongue cribs or the new Myobrace Appliances than to wait and try to treat teenagers with the same problem.
- Some young children with deep overbite and retrognathic mandibles with large overbites can have TMJ (temporomandibular joint disorders). These children can have headaches, ear problems and numerous other unpleasant symptoms. These can easily be solved with appropriate functional appliances.
- Other functional problems would include thumbsucking, which should be corrected as soon as possible.
- Skeletal problems that must be addressed early in the mixed dentition include;
 - a) Class I skeletal constricted maxillary and mandibular arches, which are the cause of the dental crowding and impacted teeth. Solutions would be to expand the upper and lower arches to make room for all the permanent teeth that will be erupting in the future.
 - b) Class II skeletal – The majority of the Class II skeletal patients has a normally positioned maxilla and an underdeveloped mandible (retrognathic). The use of functional appliances such as the removable Twin Block or the fixed MARA (Mandibular Anterior Repositioning Appliance) will advance the deficient mandible in the mixed dentition. Failure to treat early could result in the patient at age 17 having to undergo orthognathic surgery to surgically advance the mandible. The Class II correction with the functional appliances as listed previously will correct the malocclusion in 7-9 months. Obviously, mothers and children much prefer this type of treatment that is so prevalent in other countries, in Europe and in South America.
 - c) Class III skeletal – The majority of Class III skeletal patients in the mixed dentition has a midface deficiency and a prognathic profile. The maxilla is deficient. Early orthodontic treatment using fixed or removable functional appliances such as Anterior Sagittal or Tandem Appliance can successfully move the maxilla and pre-maxilla forward to create a normal maxilla and correct the Class III skeletal problem in the mixed dentition while the child is actively growing.

If treatment is not done early in the mixed dentition some of these patients will be subjected to double jaw orthognathic surgery at age 17. Obviously, mothers and children much prefer to be treated early in order to avoid surgery in the future.

- Most authorities believe that it is vital for proper health to have a patent airway that improves the level of oxygen in the blood.
- Early orthodontic treatment can have long-term health benefits for our younger patients. If you want to move your practice in the direction of improving the health of your younger patients then I would urge you to take courses to gain the knowledge to be able to help improve the long-term health of these patients. Many dentists who have taken my orthodontic courses over the years have thanked me because they were able to improve the health and malocclusions of their own children.

It is rather unfortunate that the orthodontic departments in most dental schools in North America do not teach general dentists how to utilize functional appliances in the mixed dentition. Therefore, general dentists must take orthodontic courses after graduation in order to provide these essential health services for their patients.

Summary of health benefits of early orthodontic treatment:

1. Class I Skeletal Malocclusions, constricted maxillary arch.

Many of my patients have reported after expansion of the constricted upper arch with removable or fixed functional appliance that they can breathe better through their nose. The nasal airway expands transversely and vertically. Patients also have more room for their tongue that helps improve any speech problems that might have been caused by the constricted upper arch.

Class I Malocclusions Mixed Dentition

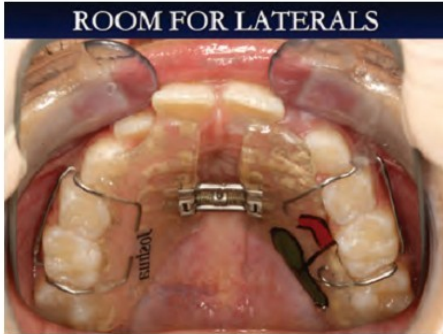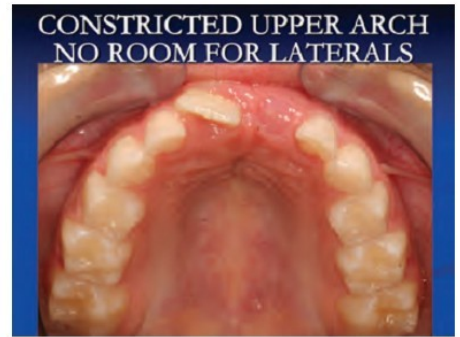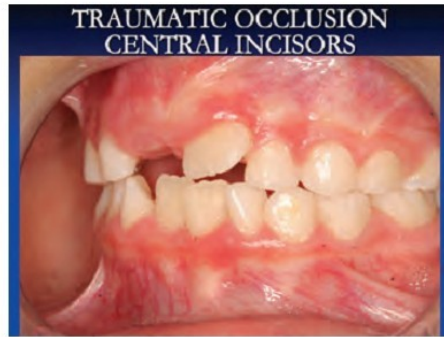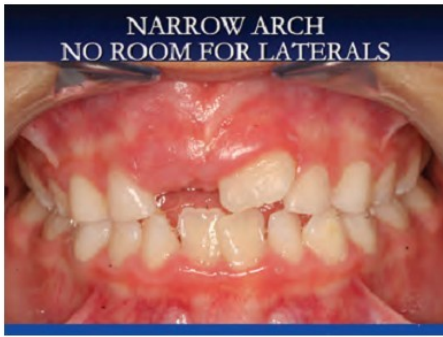Skeletal malocclusions
Narrow maxillary arch
No room for permanent teeth

Clinical signs

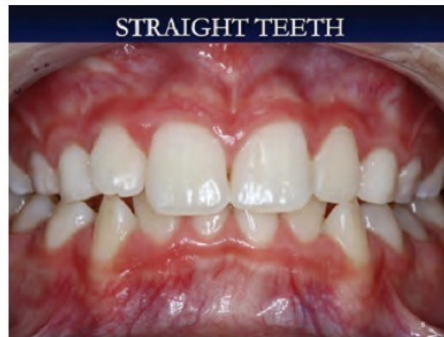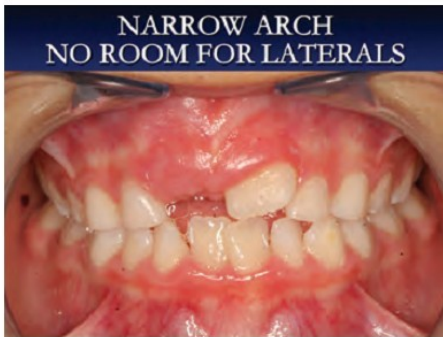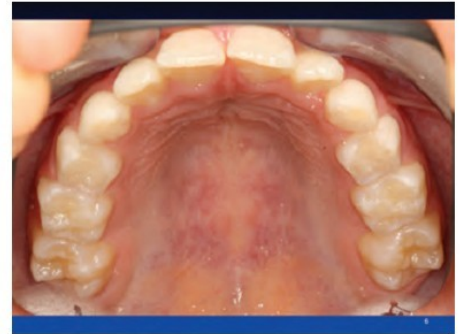No room for the permanent central and lateral incisors

Solutions

Removable Schwarz Appliance
1 midline screw
Double Adam's Clasps



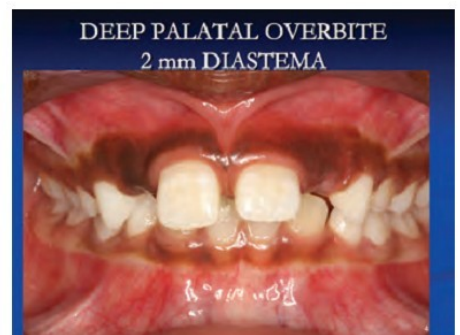
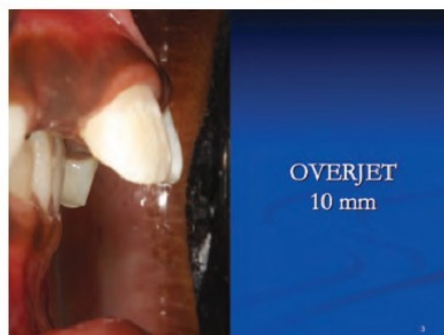WEAR ALL THE TIME
REMOVE TO CLEAN
REMOVE ACTIVE SPORTS
ADJUST MIDLINE SCREW
TURN TWICE PER WEEK
(WED, SAT)
EVERY TURN 1/4 mm



treatment of choice is use a functional jaw repositioning appliance and move the lower jaw downward and forward to correct the overjet and overbite in the mixed dentition. If there is an existing TMD problem this will correct it and also this treatment will prevent future TMD problems as the patients grow older.

2. Class II Skeletal Malocclusions, Normally Positioned Upper Jaw, Underdeveloped Lower Jaw.

Most Class II skeletal patients with normally positioned maxillas and retrognathic mandibles are predisposed to temporomandibular dysfunction. Many of these patients have their condyles posteriorly displaced and some are clicking indicating that the disc is anteriorly displaced. I have examined several children who suffer from headaches due to TMD in the mixed dentition. The treatment of choice is not to extract upper bicuspid or to retract the upper six anterior teeth. The


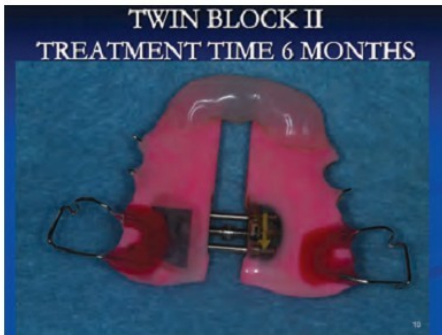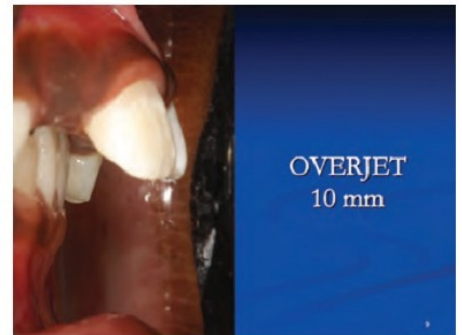
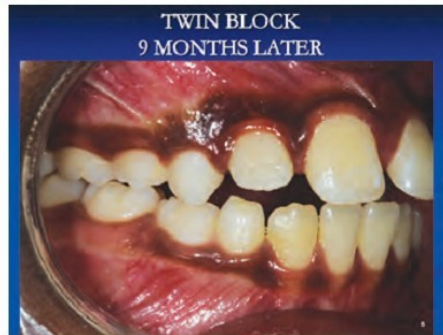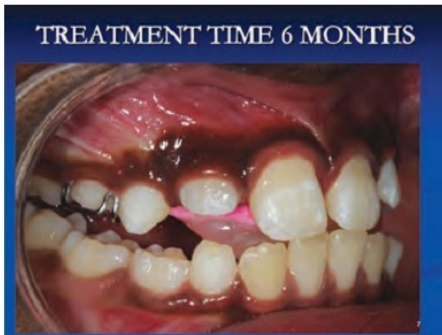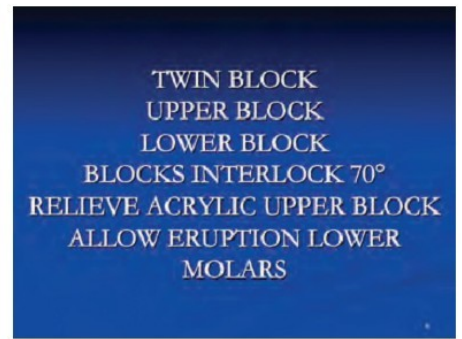


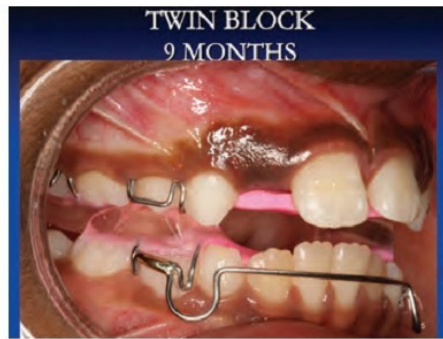Class II Malocclusions Mixed Dentition

Skeletal malocclusions
Normal maxilla
Deficient mandible

Clinical signs

Large overjet
Deep overbite
Deficient mandible



Solutions

Removable Twin Block Appliance

3. Class III Skeletal Malocclusions, Midface Deficiency, Underdeveloped Upper Jaw, Normally Positioned Lower Jaw.

The early correction of skeletal Class III malocclusions with deficient maxillas and normally positioned mandibles helps prevent the need for orthognathic surgery in the future. Failure to treat would mean at age 17 the child would have to undergo double jaw surgery and orthodontic braces from age 17-19 when they are in College or University. Why not avoid the possibility of surgical complications by using functional appliances such as the Anterior Sagittal or Tandem Appliance to correct the malocclusion in the mixed dentition in 7-9 months, non-surgically.

Recently more emphasis has been placed on patients who snore and have life- threatening obstructive sleep apnea. Surgeons are now aware that to move the lower jaw backwards surgically can also move the tongue back which can compromise the airway and make the sleep apnea problem worse. Therefore, the conclusion can be drawn that early orthodontic treatment for children with Class III skeletal problems when treated in the mixed dentition can certainly have long-term health benefits.

Class III Malocclusions Mixed Dentition

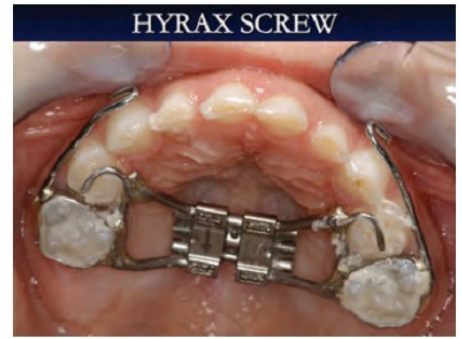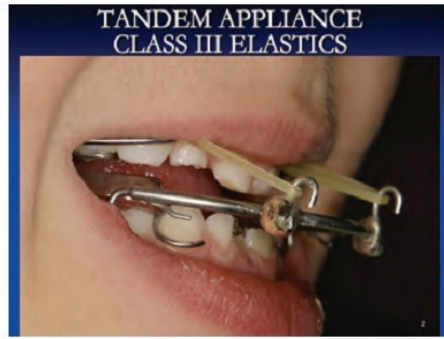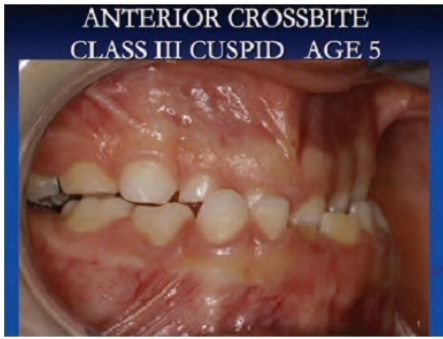Skeletal malocclusions Deficient maxilla Normal mandible

Clinical signs

Anterior crossbite
Deep overbite
Deficient maxilla

Solutions

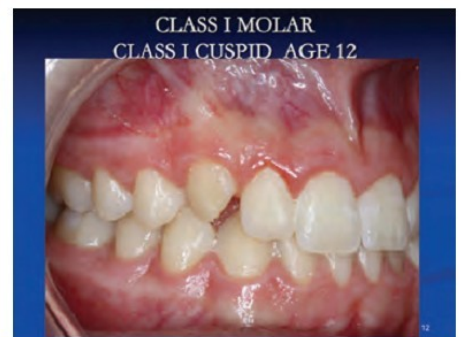

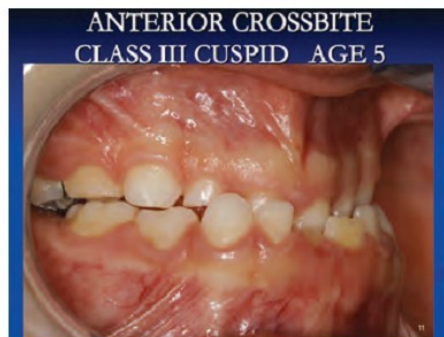
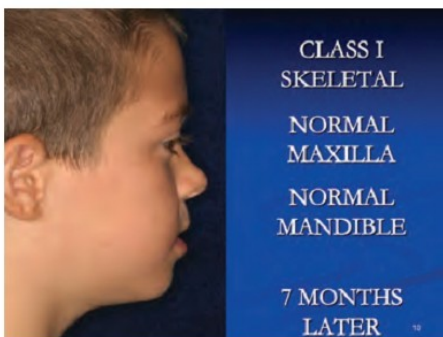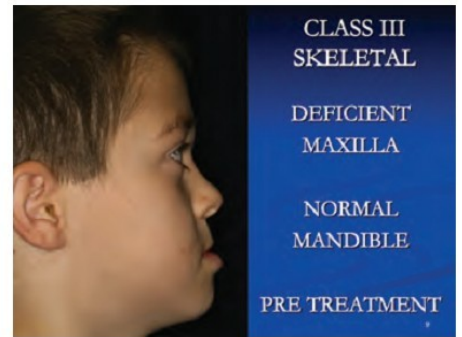
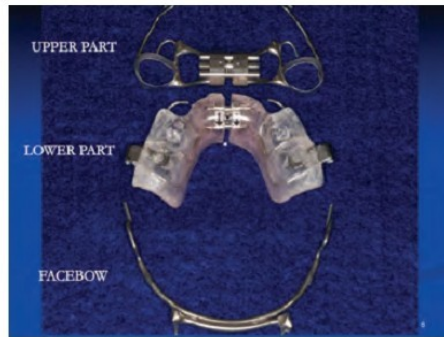
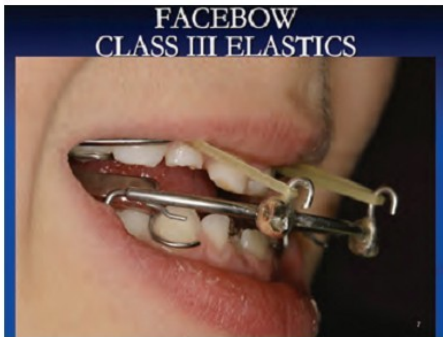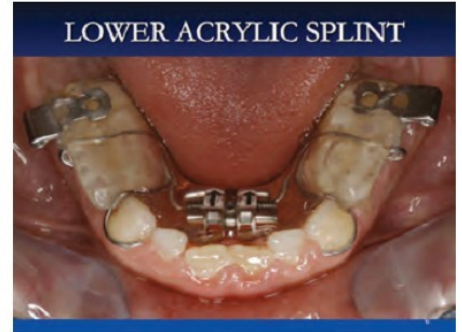
Tandem Appliance



UPPER PART TANDEM
HYRAX SCREW
BANDS SECOND PRIMARY
MOLARS
MESIAL RESTS FIRST PRIMARY
MOLARS

LOWER PART TANDEM

ACRYLIC SPLINT
BUCCAL TUBES FOR FACEBOW
MIDLINE SCREW
ADAM'S CLASP
SECOND PRIMARY MOLAR
C CLASPS LOWER CUSPIDS
(ADD COMPOSITE)



I sincerely hope that general dentists increase their awareness of these serious Orthopedic (skeletal) problems that are affecting their patients in the mixed dentition. My advice would be either to take an orthodontic course that teaches the diagnosis and treatment of children with functional appliances in the mixed dentition or to refer your patients to orthodontists who are competent to treat these very prevalent malocclusions. ■